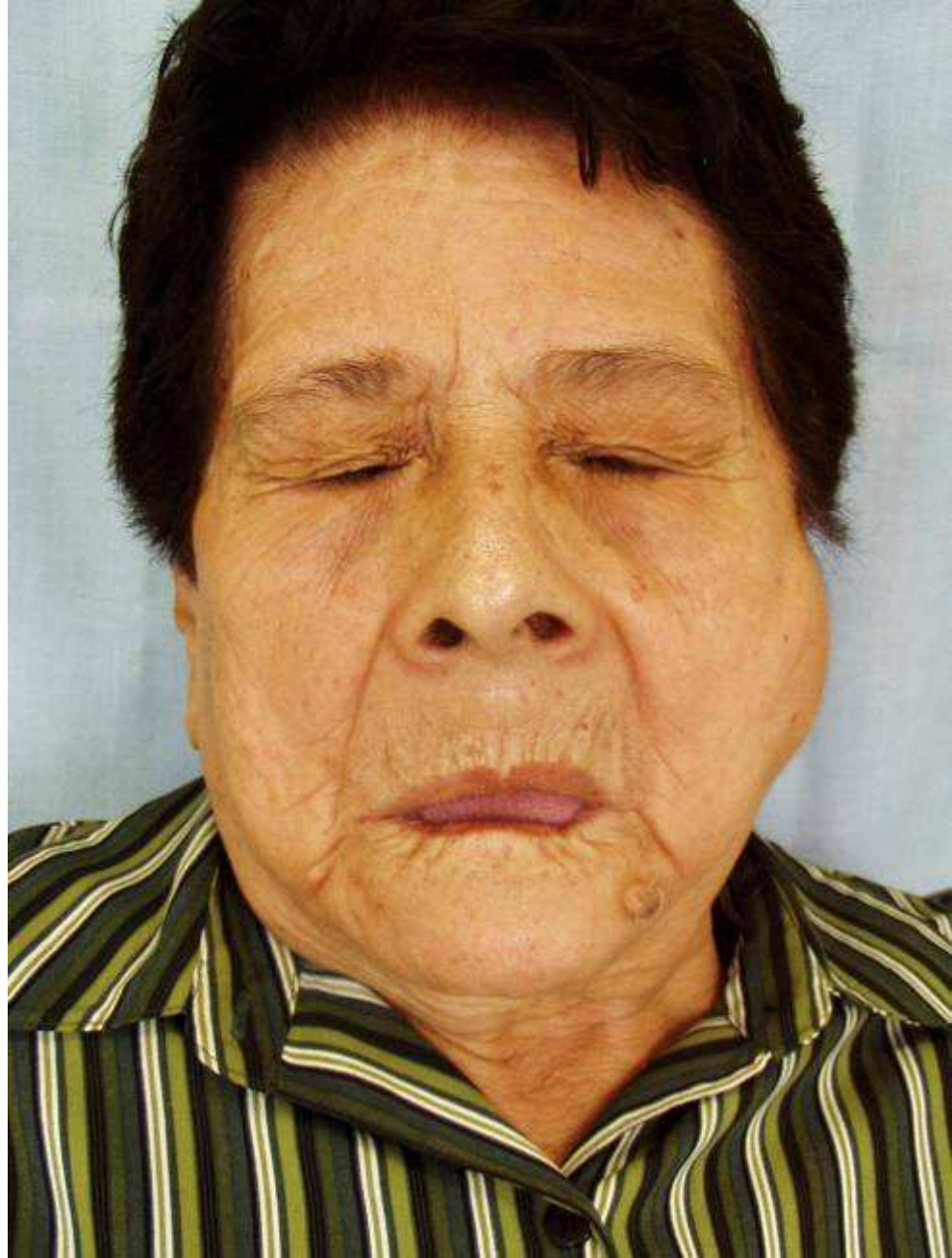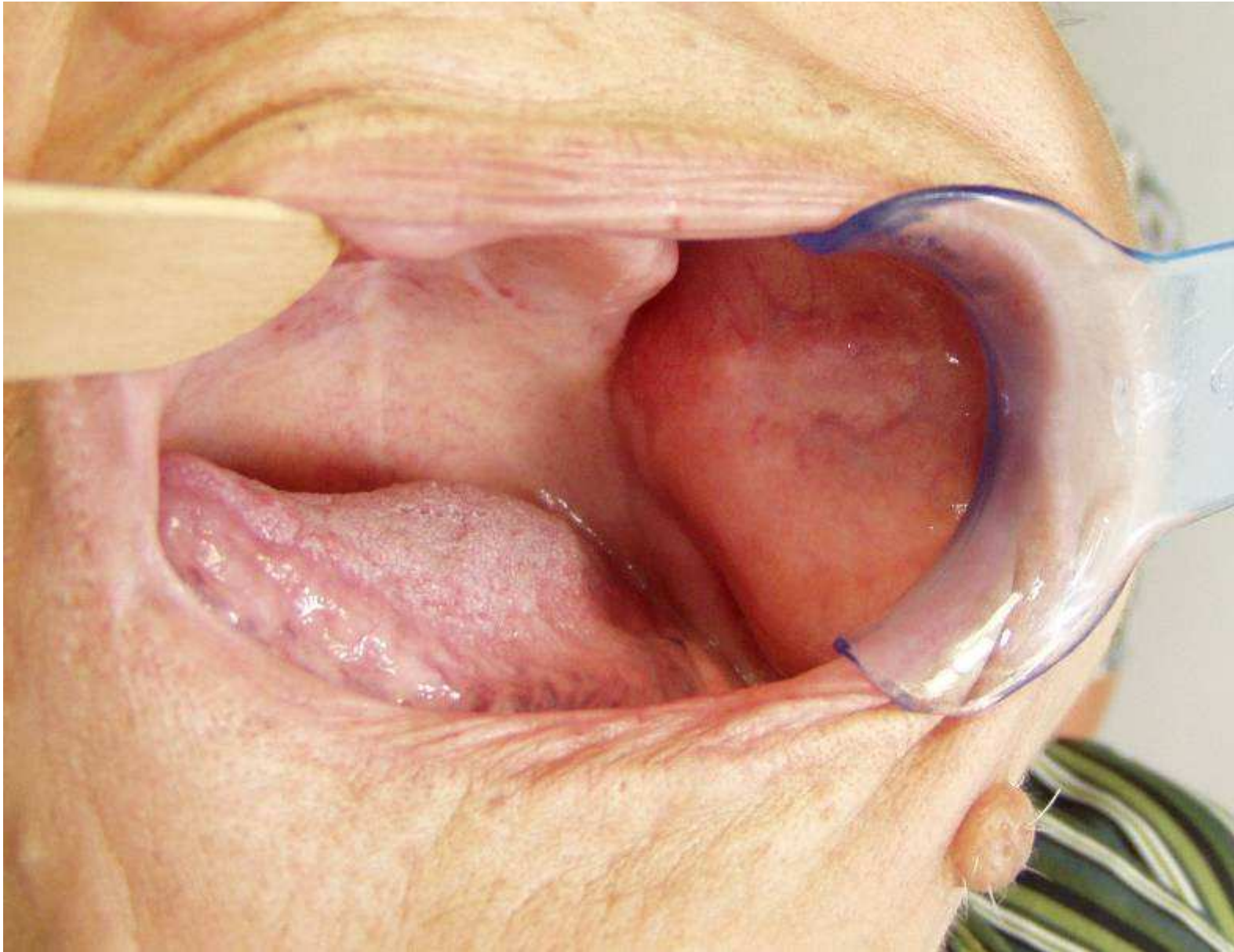

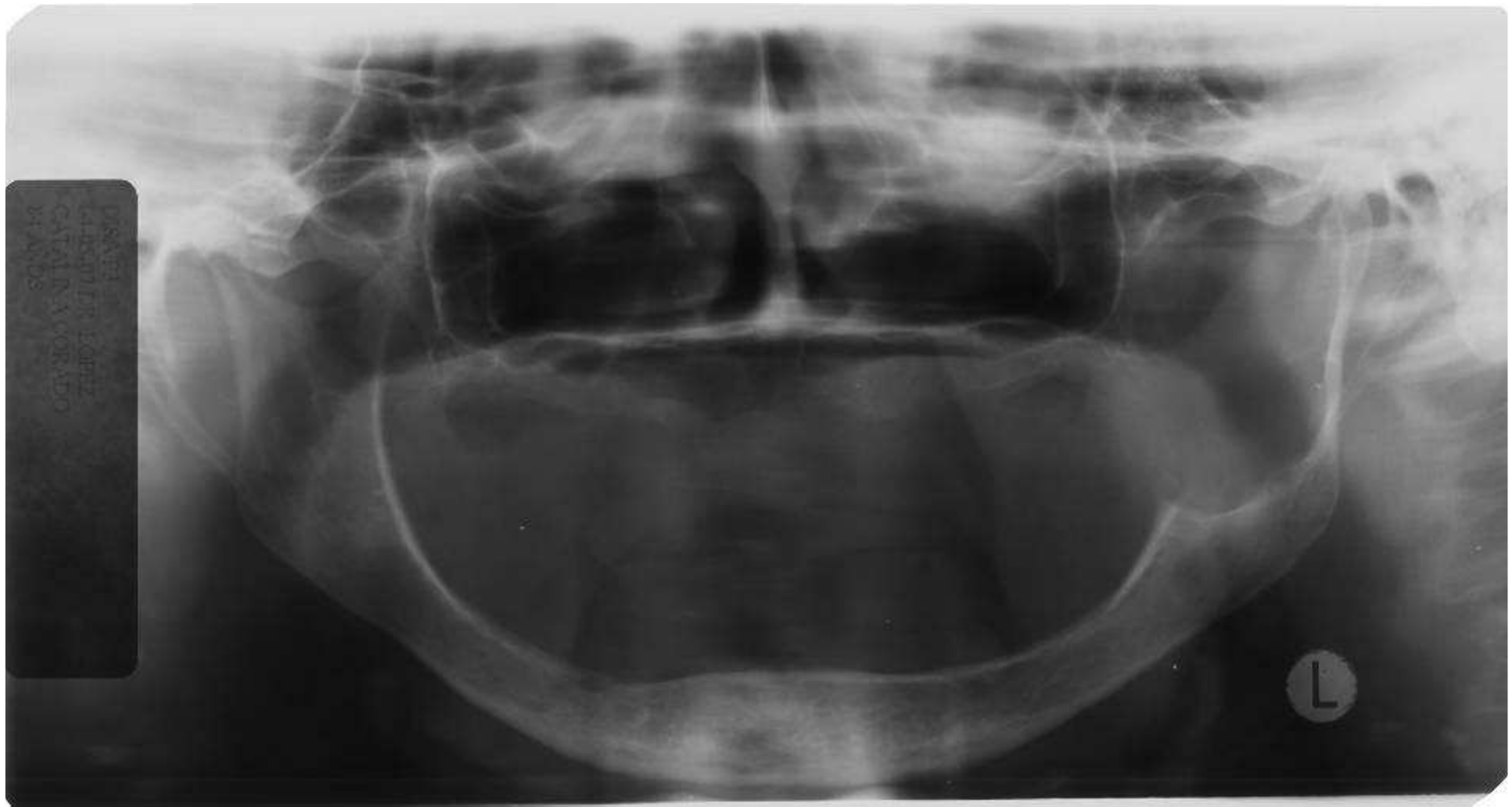
IAOP interesting case 2

This 81 year old female patient had pain and swelling in the left preauricular region. The patient had been aware of facial asymmetry for at least 5 years, with a progressive increase in the size of the swelling. There was difficulty to open the mouth.







UNIVERSITY OF CALIFORNIA
DENTISTRY
SACRAMENTO
CATALINA Y. ORLANDO
21 JAN 65

L

- A differential diagnosis based on the history and clinical and radiographic findings can be submitted.
- Respondents are also invited to indicate any other investigations they would request or perform to reach a more definitive diagnosis.
- Those who wish to participate are invited to submit their responses by email to Dr Roman Carlos at romancarlos@itelgua.com by 1 October.
- Further information will be made available to allow respondents to refine their diagnosis or offer an alternative diagnosis before the diagnosis is finally revealed.